

ВЕСТНИК КАЗНМУ



НАУЧНО-ПРАКТИЧЕСКИЙ ЖУРНАЛ

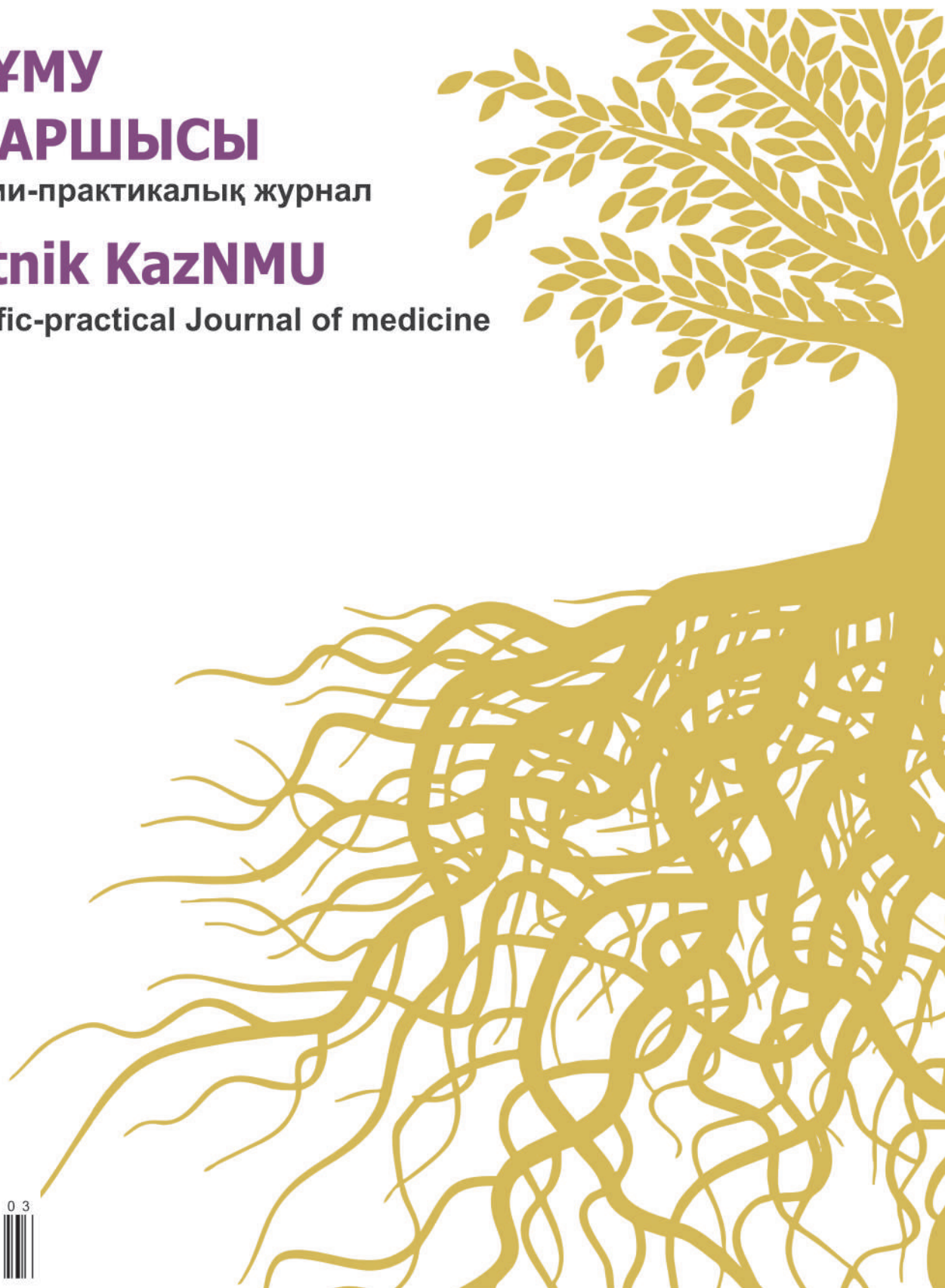
№ 1 2022

**ҚазҰМУ
ХАБАРШЫСЫ**

Ғылыми-практикалық журнал

Vestnik KazNMU

Scientific-practical Journal of medicine



ISSN 2524-0684



9 772524 068163

С.Ж. Асфендияров атындағы Қазақ Ұлттық медицина университеті

Казахский Национальный медицинский университет им. С.Д. Асфендиярова

Asfendiyarov Kazakh National Medical university

ВЕСТНИК КАЗНМУ



НАУЧНО - ПРАКТИЧЕСКИЙ ЖУРНАЛ

КАЗАХСКОГО НАЦИОНАЛЬНОГО МЕДИЦИНСКОГО УНИВЕРСИТЕТА

ҚАЗАҚ ҰЛТТЫҚ МЕДИЦИНА УНИВЕРСИТЕТІНІҢ

ХАБАРШЫСЫ

Ғылыми-практикалық журнал

VESTNIK KAZNMU

SCIENTIFIC-PRACTICAL JOURNAL OF MEDICINE

№ 1 2022

Журнал входит в перечень изданий,
рекомендованных Комитетом по контролю в сфере образования и науки МОН РК
для публикации основных результатов научной деятельности

Журнал основан в 2007 году
Минимальная периодичность
журнала 4 раза в год

Журнал 2007 жылы негізделген
Журнал жылына кем дегенде
4 рет шығады

S.A. Mussabekova¹, A.O. Stoyan²¹NJSC «Medical University of Karaganda», Karaganda city, Republic of Kazakhstan²Institute of Forensic Expertise in Almaty RSUC "Forensic Examinations Center of the Ministry of Justice of the Republic of Kazakhstan"
Almaty city, Republic of Kazakhstan

THE IMPORTANCE OF FORENSIC ASSESSMENT OF EPACTAL BONES

Resume: The observation reveals the diagnostic capabilities of forensic medical examination to resolve controversial issues arising in the establishment of the cause of death. A case of a forensic medical examination of a four-year-old child is presented to resolve the issue of the possibility of a head injury during his stay in a hospital and the degree of involvement of medical workers in his death. The detection of an intercalary bone formed as a result of the appearance of additional ossification points in the large fontanel in the embryonic period and which is a congenital malformation during a forensic study indicates the absence of traumatic brain injury. The interdisciplinary approach made it possible to completely exclude the possibility of a child getting a head injury in a hospital.

Key words: infant mortality, forensic medical examination, skull bones, trauma, developmental anomalies.

C.A. Мусабекова¹, А.О. Стоян²¹Қарағанды медицина университеті, Қарағанды қ., Қазақстан²Алматы қаласы бойынша сот сараптамалары институты "ҚР ӘМ Сот сараптамасы орталығы" РМҚК, Алматы қ., Қазақстан

ЕНДІРМЕ СҮЙЕКТЕРІН СОТ-МЕДИЦИНАЛЫҚ БАҒАЛАУДЫҢ МАҢЫЗДЫЛЫҒЫ

Түйін: Байқауда өлімнің себебін анықтау кезінде туындайтын даулы мәселелерді шешу үшін медициналық-криминалистикалық сараптаманың диагностикалық мүмкіндіктері ашылады. Стационарда болу барысында оның басынан жарақат алу мүмкіндігі және медицина қызметкерлерінің оның өліміне қатыстылық дәрежесі туралы мәселені шешу үшін төрт жасар балаға сот-медициналық сараптама жүргізу жағдайы ұсынылды. Медициналық-криминалистикалық зерттеу жүргізу кезінде үлкен еңбекте эмбриональды кезеңде сүйектенудің қосымша нүктелерінің пайда болуы нәтижесінде пайда болған және дамудың туа біткен аномалиясы болып табылатын қондырма сүйегін анықтау ми жарақатының жоқтығын көрсетеді. Пәнаралық тәсіл баланың бас жарақатын емдеу мекемесінде алу мүмкіндігін толығымен жоққа шығарды.

Түйін сөздер: балалар өлімі, сот-медициналық сараптама, бас сүйек сүйектері, жарақат, даму аномалиялары.

C.A. Мусабекова¹, А.О. Стоян²¹НАО «Медицинский университет Караганды», город Караганда, Республика Казахстан²Институт судебных экспертиз по г.Алматы РГКП «Центр судебной экспертизы МЮ РК», город Алматы, Республика Казахстан

ВАЖНОСТЬ СУДЕБНО-МЕДИЦИНСКОЙ ОЦЕНКИ ВСТАВОЧНЫХ КОСТЕЙ

Резюме: В наблюдении раскрываются диагностические возможности медико-криминалистической экспертизы для решения спорных вопросов, возникающих при установлении причины смерти. Представлен случай проведения судебно-медицинской экспертизы четырехлетнего ребёнка для решения вопроса о возможности получения им травмы головы в ходе пребывания в стационаре и степени причастности медицинских работников к его гибели. Обнаружение при проведении медико-криминалистического исследования вставочной кости, образованной в результате возникновения в большом родничке дополнительных точек окостенения в эмбриональном периоде и являющейся врожденной аномалией развития, свидетельствует об отсутствии черепно-мозговой травмы. Междисциплинарный подход позволил полностью исключить возможность получения ребенком травмы головы в лечебном учреждении.

Ключевые слова: детская смертность, судебно-медицинская экспертиза, кости черепа, травма, аномалии развития.

Introduction

The World Health Organization (WHO) and the international organization United Nations Children's Fund (UNICEF) have repeatedly noted that infant and child mortality (in the first five years of life), along with life expectancy, are an integral indicator of the quality of life in a particular region [12]. One of the leading indicators of the state of health of the child population, mortality in childhood, is an important component in the process of characterizing the demographic situation in the country and is considered as the main criterion not only for protecting the health of mothers and children, but also for

the state of the national health system as a whole [3,4,12]. All death cases of children under 5 years of age are subject to careful analysis and clinical discussion [3,10]. According to UNICEF data over the past year, the main causes of infant mortality in Kazakhstan are non-compliance by medical workers with existing standards and algorithms, a shortage of neonatologists, insufficient knowledge and skills, and the lack of a unified approach to the use of antimicrobial drugs [12]. Both in frequency and in the structure of causes, a mortality in infancy differs in its various periods [3,4,10]. However, the death of children of this age group in inpatient institutions is not always



associated with incorrect actions of doctors in their treatment [2,8]. External influences, certain conditions arising in the perinatal period, and congenital anomalies remain the absolute leading causes of mortality in the child population in many countries [4,10]. Analyzing the main causes of death of children in Kazakhstan, special emphasis should be paid to the high mortality rate of children under 5 years of age from congenital malformations, various injuries and other causes [4]. One of the urgent problems of the health care system in Kazakhstan is improving the quality of medical care to the population [3,4,7]. At the same time, a significant role in assessing the quality of medical care is assigned to forensic medical examination [7]. To date, there has been a steady increase in the number of lawsuits filed by patients in connection with the inadequate quality of medical care, leading to an increase in the number of forensic medical examinations in civil cases.

Irregular bones of the skull (Wormian, sutural, epactal, Andernach's ossicles) are additional bones that form along the sutures in the fontanelles due to the appearance of additional ossification points in the bones of the skull. Such features are small developmental anomalies, and are most often an accidental finding during X-ray examination of the skull of children under the age of 5 years [6,10]. Irregular bones of the skull are often found in defects of the skull, in osteogenesis imperfecta, as well as in combination with congenital malformations of the brain [9]. Until the middle of the last century, it was believed that epactal bones had no medical significance. However, a number of authors have noted that unilateral suture bones are a convincing sign of brain damage [5]. Literary data testify to numerous finds of epactal bones of the skull during archaeological excavations [6,10]. At the same time, specialists do not provide a detailed description and microscopy of the additional bones, and in such cases such sources have no forensic value. Meanwhile, the main significance of irregular bones of the skull in forensic practice, under certain circumstances of the case, is that they can be mistakenly regarded as fragments [1,9]. This fact can negatively affect the subsequent delivery of a court decision. Taking into account all possible options for the development of anomalies, correct medical and forensic assessment of the skull bones plays an important role in ascertaining the true cause of death. The message under consideration clearly demonstrates the role of forensic research in the diagnosis of trauma in all controversial cases and reveals the importance of its timely and comprehensive implementation for solving specific forensic medical problems.

Case presentation

In this case, a commissioned forensic medical examination was carried out in connection with the initiation of a criminal case on the possible infliction of serious harm to

the health of a child in a hospital. For a forensic study on the death of a four-year-old child, a skin flap and skull bones were provided to the forensic department. According to the circumstances of the case: "The reasons for the death of the minor have not been fully established". However, according to the statement, the mother of the child «... asks to adopt legal measures against the medical staff of the children's hospital.... where her child died due to their improper performance of professional duties». For the permission of the forensic medical examination, the question of determining the mechanism of the formation of injuries on the child's body, discovered during the commission of the forensic medical examination was raised. According to the conclusion of the forensic examiner, an internal examination of the corpse revealed: that hemorrhage on the skin of the parietal region of a dark brown color, irregular in shape with indistinct contours, measuring about 5.0x2.0 cm (**Figure 1**) and a quadrangular bone plate measuring about 1.9 x 3.0 x 2.0x3.1 cm (presumably the area of the large fontanelle), which was connected with the frontal and parietal bones through the sutures of the skull (**Fig.2**).

A skin flap from the corpse of a child presented for examination is dry, dark in color, dense to the touch. To restore the original properties, the skin flap was placed for three days in an alcohol-vinegar solution (Ratnevsky's solution). After that, for clarification, the above-mentioned flap was placed for two hours in a solution of alcohol-vinegar solution with the addition of hydrogen peroxide (Ratnevsky's solution №2). After the reconstruction of the skin flap, a medical and forensic research was carried out: no damage was found during visual and stereomicroscopic examination of the skin preparation (**Figure 3**) (**Figure 4**). During the medical and forensic examination of a fragment of the frontal bone, two fragments of the parietal bones and the epactal bone of the child's skull, it was found: the bones of the skull are yellow-brown, hard, solid, light, smooth to the touch, with an oily sheen. The above-mentioned fragments of bones for three days were placed in an alcohol-vinegar solution with the addition of hydrogen peroxide to restore (Ratnevsky's solution №2). The research established: the epactal bone is connected to a fragment of the frontal bone by a sagittal suture, and its connection with fragments of the parietal bones is carried out using abnormal sutures of the skull. In this case, all of the above-mentioned fragments of bones are completely comparable (**Figure 5**) (**Figure 6**). Stereomicroscopic examination of the provided fragments showed that the teeth of the sutures are quite marked, not crushed or displaced. No damage was found on the bones of the skull. The intercalation bone could have formed as a result of the appearance in the large fontanelle of additional ossification points in the embryonic period, which is a congenital malformation.

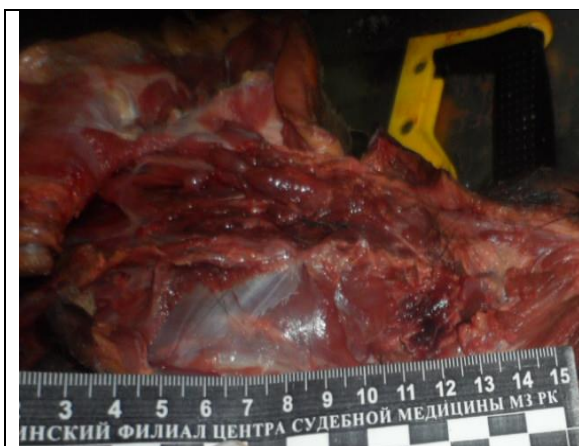

Figure 1 - Hemorrhage into the skin of the occipital region, detected during a forensic examination of a corpse

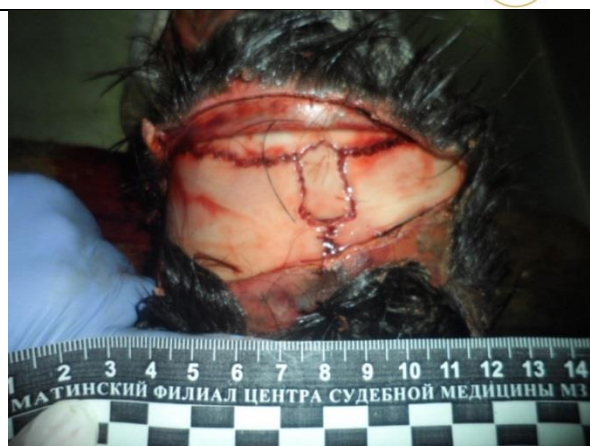

Figure 2 - View of the bones of the cranial vault during exhumation

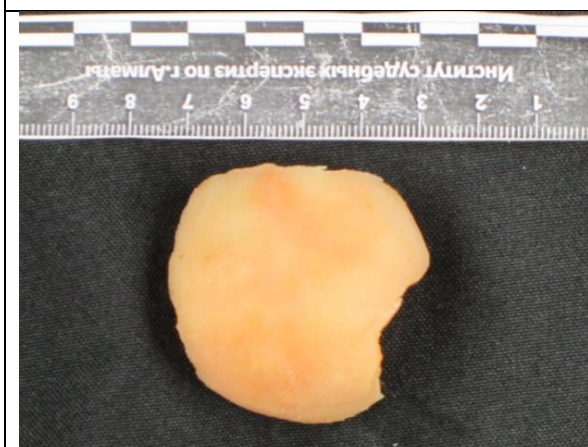

Figure 3 - Skin flap after recovery

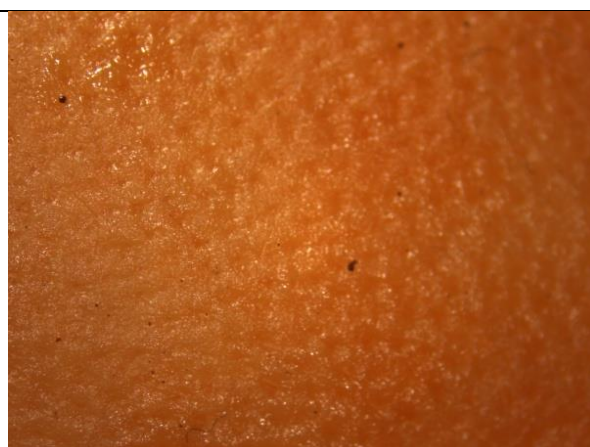

Figure 4 - Stereomicroscopic picture of a skin flap



Figure 5 - Skull bones, outside view

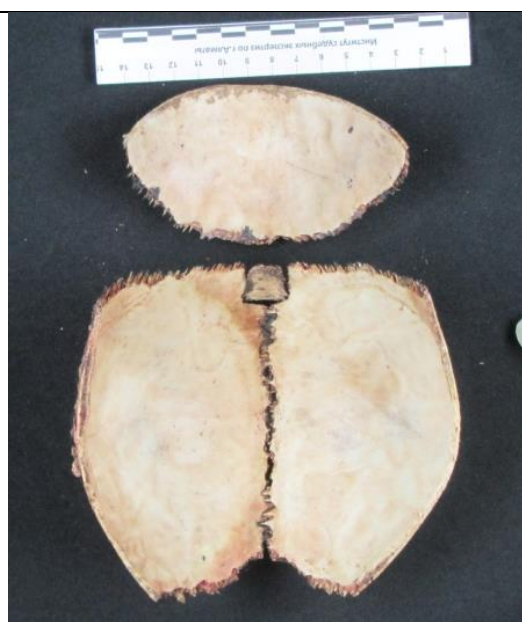


Figure 6 - Skull bones, inside view

Discussion:

The literature on forensic fractology describes in detail the morphological characteristics of fractures of the skull bones, which are formed as a result of impact when falling or when the head is compressed [11,13]. At the same time, the type of fractures is mediated by the peculiarities of the trauma mechanism, that is, in each specific case, according

to the morphological features of injuries to the bones of the skull or their fragments, one can judge the possible conditions corresponding to certain biomechanical patterns of the formation of trauma to the bones of the skull [11]. The morphological features of fragments of the child's skull revealed during the medical and forensic examination made it possible to exclude the possibility of



their formation as a result of the shock mechanism of a skull injury in a single fall from a height of about 1 meter or hitting the head on the floor. Meanwhile, it was found that the identified epactal bone (insular, suture, Wormian) could have formed as a result of the appearance of additional ossification points in the bones of the cranial vault in the embryonic period, which is a congenital developmental anomaly. According to A.A. Zajchenko et al. the insular bones of the skull are included in the form of islets in typical bones adjacent to the sutures and are formed from centers of ossification enclosed in the membranous tissue of the fontanelles [5]. By their characteristic location - along the seam, serrated contours, thin linear enlightenment separating them from the main bone and the zone of «physiological sclerosis», they are distinguished from bone fragments and sequesters [11]. For practical medicine, knowledge of possible options for the location of inconsistent bones of the skull is determined mainly by the fact that in case of head injuries or on X-ray images they can be mistaken for cracks or bone fragments, as described in the literature [13]. Forensic medical examination is able to provide adequate explanations for the formation of certain injuries, especially if there are doubts about the origin of some nonspecific elements found during autopsy [1,7]. However, in some cases, a more detailed analysis of the mentioned material is needed, with a justification of the mechanism of damage formation or existing anomalies. Forensic medical examination is an important step in ascertaining the true cause of a person's death. However, it is the medical and forensic examination that makes it possible to establish a detailed description of a congenital small anomaly of development and to judge the mechanism of its formation, taking into account knowledge about the morphological patterns of the

formation of skull fractures from classical forensic fracture science, thus solving a complex forensic medical problem that has an important legal meaning.

Authors' Contributions. All authors participated equally in the writing of this article.

No conflicts of interest have been declared.

This material has not been previously submitted for publication in other publications and is not under consideration by other publishers.

There was no third-party funding or medical representation in the conduct of this work.

Funding - no funding was provided.

Авторлардың үлесі. Барлық авторлар осы мақаланы жазуға тең дәрежеде қатысты.

Мүдделер қақтығысы – мәлімделген жоқ.

Бұл материал басқа басылымдарда жариялау үшін бұрын мәлімделмеген және басқа басылымдардың қарауына ұсынылмаған.

Осы жұмысты жүргізу кезінде сыртқы ұйымдар мен медициналық өкілдіктердің қаржыландыруы жасалған жоқ.

Қаржыландыру жүргізілмеді.

Вклад авторов. Все авторы принимали равносильное участие при написании данной статьи.

Конфликт интересов – не заявлен.

Данный материал не был заявлен ранее, для публикации в других изданиях и не находится на рассмотрении другими издательствами.

При проведении данной работы не было финансирования сторонними организациями и медицинскими представителями.

Финансирование – не проводилось.

СПИСОК ЛИТЕРАТУРЫ

- 1 Авдеев А.И., Компанец Н.Ю. Экспертная оценка лицевой и черепно-мозговой травмы. // Судебная медицина. - 2016. - №2(3). - С. 13-16.
- 2 Антонова Е.Ю. Ответственность за ненадлежащее выполнение профессиональных обязанностей медицинским или фармацевтическим работником по уголовному законодательству Республики Казахстан // Журнал зарубежного законодательства и сравнительного правоведения. 2018. №1 (68). URL: <https://cyberleninka.ru/article/n/otvetstvennost-zanadlezhaschee-vypolnenie-professionalnyh-obyazannostey-meditsinskim-ili-farmatsevticheskim-rabotnikom-po> (дата обращения: 31.10.2021).
- 3 Баранов А.А., Альбицкий В.Ю., Намазова-Баранова Л.С. Смертность детского населения в России: состояние, проблемы и задачи профилактики // Вопросы современной педиатрии. - 2020. - №19(2). - С.96-106.
- 4 Байсеркина Ф. Основные тенденции детской смертности в Казахстане // Журнал клинической медицины Казахстана. - 2014. - №2 (32). - С. 54-9.
- 5 Зайченко А.А., Журкин К.И. Кости швов и родничков свода черепа человека // Саратовский научно-медицинский журнал. - 2017. - №13(2). - С. 209-212.
- 6 Майтбасова Р.С., Хабижанов Б.Х., Кайназарова С.Е., Шарипова М.Н., Нургазиева С.Н., Нурғалиева Ж.Ж. Структура врожденных пороков развития детей, умерших в возрасте до 5 лет // Вестник КазНМУ. 2014. №2-4. URL: <https://cyberleninka.ru/article/n/struktura-vrozhdennyh-porokov-razvitiya-detey-umerших-v-vozraste-do-5-let> (дата обращения: 31.10.2021).

- 7 Мусабекова С.А. Судебная медицина: новые пути - новые возможности // Вестник КазНМУ. 2016. №4. URL: <https://cyberleninka.ru/article/n/sudebnaya-meditsina-novye-puti-novye-vozmozhnosti> (дата обращения: 31.10.2021).
- 8 Пархоменко С.В., Демченко В.А. Проблемы уголовно-правовой оценки субъективных признаков халатности медицинских работников при осуществлении профессиональной деятельности // Сибирский юридический вестник. - 2019. - №3. - URL: <https://cyberleninka.ru/article/n/problemy-ugolovno-pravovoy-otsenki-subektivnyh-priznakov-halatnosti-meditsinskih-rabotnikov-pri-osuschestvlenii-professionalnoy> (дата обращения: 31.10.2021).
- 9 Рыбаков А.Г., Лошкарев И.А., Мачинский П.А., Кадыров А.Ш., Паршин А.А. Вариантная анатомия непостоянных отверстий средней черепной ямки // Современные проблемы науки и образования. - 2017. № 6. URL: <https://science-education.ru/ru/article/view?id=27177> (дата обращения: 31.10.2021).
- 10 Туманова У.Н., Шувалова М.П., Щеголев А.И. Анализ статистических показателей врожденных аномалий как причины ранней неонатальной смерти в Российской Федерации // Российский вестник перинатологии и педиатрии. - 2018. - №63(6). - С. 60-67.
- 11 Kranioti E. Forensic investigation of cranial injuries due to blunt force trauma: current best practice // Research and Reports in Forensic Medical Science. - 2015. - №5. - P.25-37.



12 UNICEF. Levels and Trends in Child Mortality [internet-istochnik] – <https://data.unicef.org> – data obrasheniya 26.06.2021

13 Wei F., Bucak S.S., Vollner J.M., Fenton T.W., Jain A.K., Haut R.C. Classification of Porcine Cranial Fracture Patterns Using a Fracture Printing Interface // Journal of Forensic Sciences. - 2017. - №62(1). - P. 30-38.

REFERENCES

- 1 Avdeev A.I., Kompanets N.Yu. Ekspertnaya otsenka litsevoy i cherepno-mozgovoy travmy // Sudebnaya meditsina. - 2016. - №2(3). - Pp. 13-16. [in Russian]
- 2 Antonova E.Yu. Otvetstvennost' za nenadlezhashchee vypolnenie professional'nykh obyazannostey meditsinskim ili farmatsevticheskim rabotnikom po ugolovnomu zakonodatel'stvu Respubliki Kazakhstan // Zhurnal zarubezhnogo zakonodatel'stva i sravnitel'nogo pravovedeniya. - 2018, 1(68). Available at: <https://cyberleninka.ru/article/n/otvetstvennost-za-nenadlezhashchee-vypolnenie-professionalnyh-obyazannostey-meditsinskim-ili-farmatsevticheskim-rabotnikom-po> (accessed 31.10.2021). [in Russian]
- 3 Baranov A.A., Al'bitskiy V.Yu., Namazova-Baranova L.S. Smertnost' detskogo naseleniya v Rossii: sostoyanie, problemy i zadachi profilaktiki // Voprosy sovremennoy pediatrii. - 2020. - №19(2). - Pp. 96-106. [in Russian]
- 4 Bayserkina F. Osnovnye tendentsii detskoy smertnosti v Kazakhstane // Zhurnal klinicheskoy meditsiny Kazakhstana. - 2014. - №2 (32). - Pp. 54-9. [in Russian]
- 5 Zaychenko A.A., Zhurkin K.I. Kosti shvov i rodnichkov svoda cherepa cheloveka // Saratovskiy nauchno-meditsinskiy zhurnal. - 2017. - №13(2). - Pp. 209-212. [in Russian]
- 6 Maytbasova R.S., Khabizhanov B.Kh., Kaynazarova S.E., Sharipova M.N., Nurtazaeva S.N., Nurgalieva Zh.Zh. Struktura vrozhdennykh porokov razvitiya detey, umershikh v vozraste do 5 let // Vestnik KazNMU. - 2014. - S. 2-4. Available at: <https://cyberleninka.ru/article/n/struktura-vrozhdennykh-porokov-razvitiya-detey-umershikh-v-vozraste-do-5-let> (accessed 31.10.2021).
- 7 Musabekova S.A. Sudebnaya meditsina: novye puti - novye vozmozhnosti. // Vestnik KazNMU. - 2016, 4. Available at:

- <https://cyberleninka.ru/article/n/sudebnaya-meditsina-novye-puti-novye-vozmozhnosti> (accessed 31.10.2021). [in Russian]
- 8 Parkhomenko S.V., Demchenko V.A. Problemy ugolovno-pravovoy otsenki sub"ektivnykh priznakov khalatnosti meditsinskikh rabotnikov pri osushchestvlenii professional'noy deyatel'nosti // Sibirskiy yuridicheskiy vestnik. 2019, 3. Available at: <https://cyberleninka.ru/article/n/problemy-ugolovno-pravovoy-otsenki-subektivnykh-priznakov-halatnosti-meditsinskikh-rabotnikov-pri-osushchestvlenii-professionalnoy> (accessed 31.10.2021). [in Russian]
- 9 Rybakov A.G., Loshkarev I.A., Machinskiy P.A., Kadyrov A.Sh., Parshin A.A. Variantnaya anatomiya nepostoyannykh otverstiy sredney cherepnoy yamki // Sovremennye problemy nauki i obrazovaniya. 2017, 6. Available at: <https://science-education.ru/ru/article/view?id=27177> (accessed 31.10.2021). [in Russian]
- 10 Tumanova U.N., Shuvalova M.P., Shchegolev A.I. Analiz statisticheskikh pokazateley vrozhdennykh anomalii kak prichiny ranney neonatal'noy smerti v Rossiyskoy Federatsii // Rossiyskiy vestnik perinatologii i pediatrii. 2018. - №63(6). - Pp. 60-67. [in Russian]
- 11 Kranioti E. Forensic investigation of cranial injuries due to blunt force trauma: current best practice. // Research and Reports in Forensic Medical Science. - 2015. - №5. - Pp. 25-37.
- 12 UNICEF. Levels and Trends in Child Mortality [internet-istochnik] – Available at: <https://data.unicef.org> – accessed 26.06.2021.
- 13 Wei F., Bucak S.S., Vollner J.M., Fenton T.W., Jain A.K., Haut R.C. Classification of Porcine Cranial Fracture Patterns Using a Fracture Printing Interface // Journal of Forensic Sciences. - 2017. - №62(1). - Pp. 30-38.

The address of the author responsible for correspondence with the editors:

Saule Amangeldiyevna Mussabekova

Candidate of Medical Sciences,

Professor of the Department of Pathology of the Nonstock Corporation "Medical University of Karaganda",

master level forensic medical expert

ORCID: 0000-0001-9622-8218 <https://orcid.org/0000-0001-9622-8218>

100009, Republic of Kazakhstan

Karaganda city,

MusabekovaS@qmu.kz